

# Success over the long term

**Philippe Jourdan** presents an implant placement case which has stood the test of time.

The patient, a woman aged around 60 years old, presented with a fractured root of her upper right premolar (fig 1). A long-term patient of the practice, she was otherwise in a state of good oral health.

## Assessment

After an initial assessment, it was discovered that a cyst had developed around the fractured tooth, with the serious infection necessitating surgical extraction (fig 2). The patient was advised of the options open to her: either a bridge or an implant, and the benefits and potential drawbacks of both. After consideration, she chose the latter and the treatment could proceed.

## Extraction

The extraction was a smooth, unhindered process; because of its fractured state, the tooth came out in two pieces (fig 3). Care was taken to maintain the small bridge of bone on the buccal side (figs 4 and 5); this would serve as a vital scaffold for the implant, for the bone substitute and for micro-vascularisation at the site.

Surgery was performed with a flap, because of the need for greater visibility due to the presence of advanced granulation.

## Preparation

Following the extraction, a burr was used to thoroughly clean the cavity except for the crucial remaining bone fragment (fig 6). The burr prepared the



**Philippe Jourdan**

is a private dentist working at Balma Dental Clinic, France.

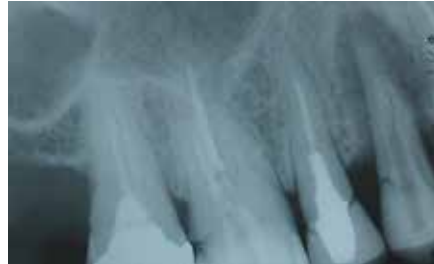


Fig 1.

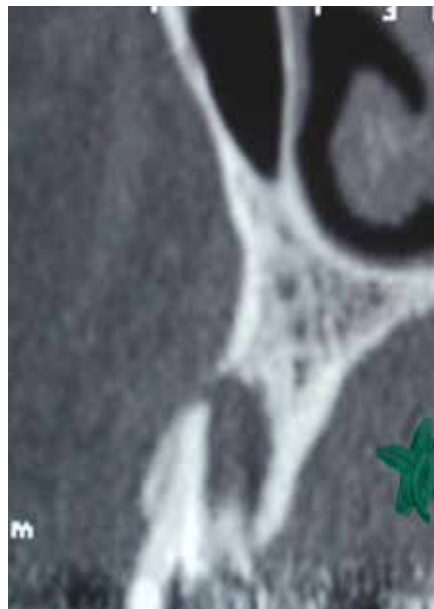


Fig 2.

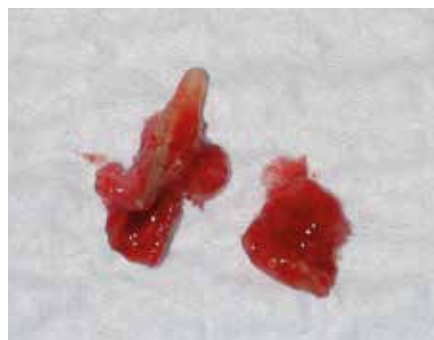

Fig 3.

fenestration site, with the cavity on the buccal side of the bone. The burr was used for drilling purposes and for preparation for the implant because piezoelectric technology was not available at the time.

## Implant placement

The Z1 implant was chosen because of

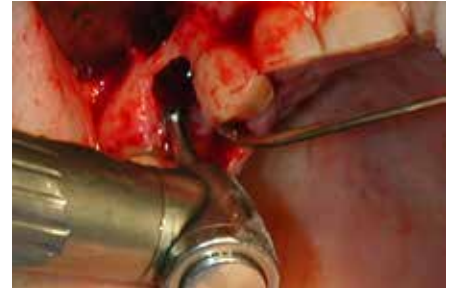


Fig 4.

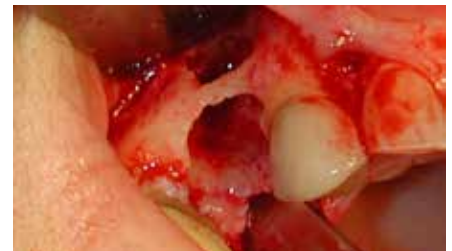

Fig 5.

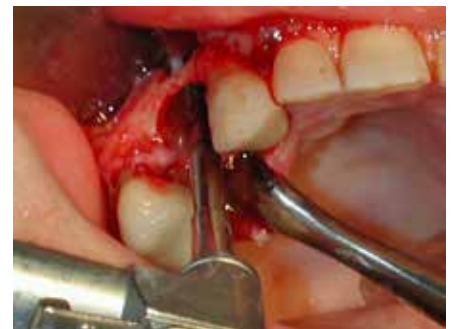

Fig 6.

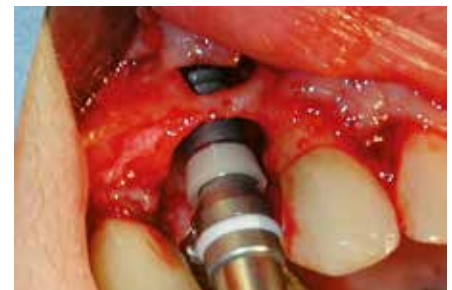

Fig 7.

its excellent periodontal integration and suitability for immediate implantation (figs 7 and 8). The socket required a graft of PRF and bone substitute (fig 9), to ensure efficient and safe healing of the tissues around the implant. Despite the trauma around the placement site, there was enough primary stability to ensure later osseointegration. One ➔

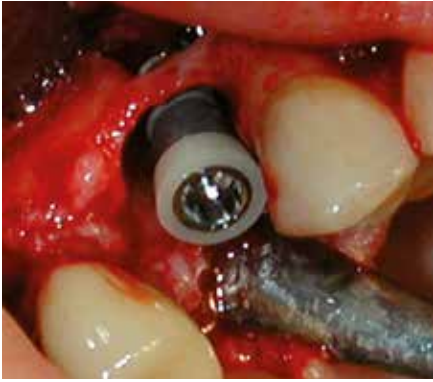


Fig 8.

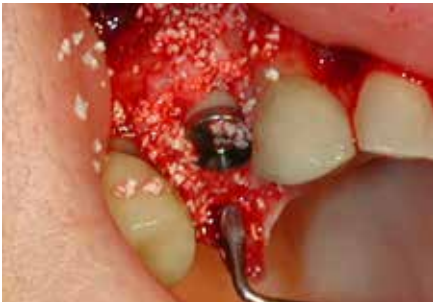

Fig 9.

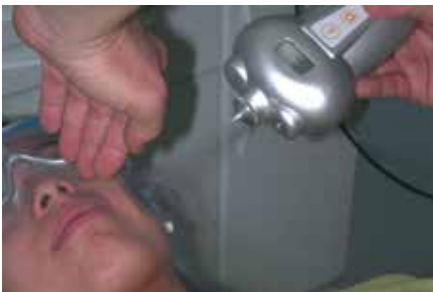

Fig 10.

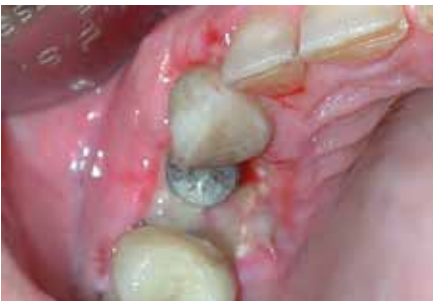

Fig 11.

One-third of the implant had good apical stability, which, in this case, was acceptable.

Cryotherapy was then used to prevent inflammation and oedema (fig 10). The operation, with no unexpected developments or complications, lasted an hour.

Antibiotics were also prescribed post-surgery due to the severe infection at the implant site.

### Healing period

The healing process was non-

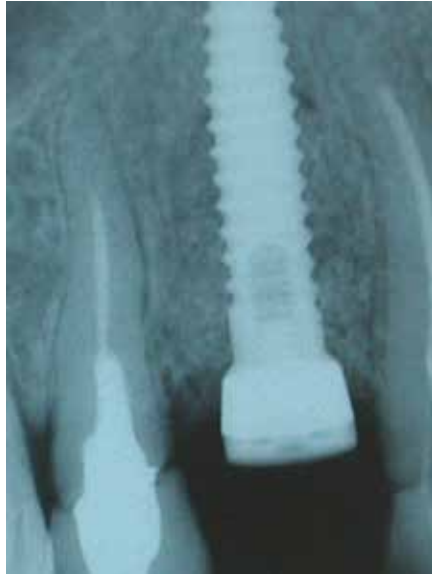

Fig 12.

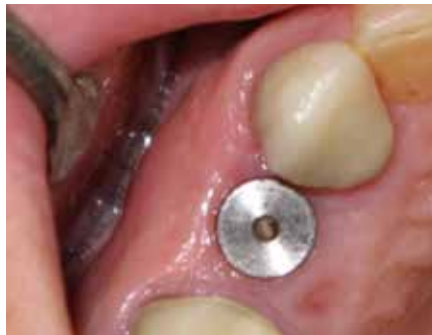

Fig 13.

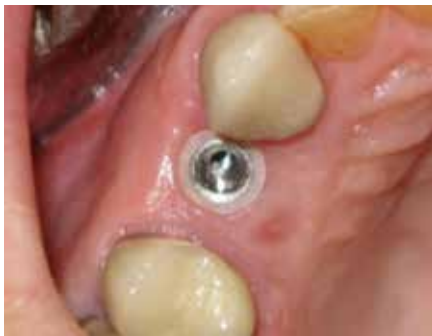

Fig 14.

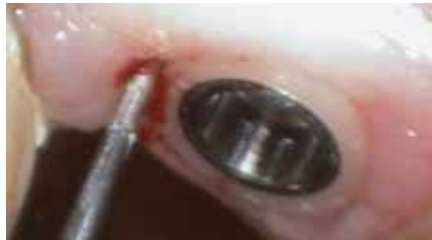

Fig 15.

problematic, and is evident eight days after surgery despite the inflamed appearance (figs 11 and 12). Five months later, the osseointegration and the gingival integration process had also been successful (fig 13), a highly pleasing result due to the severe

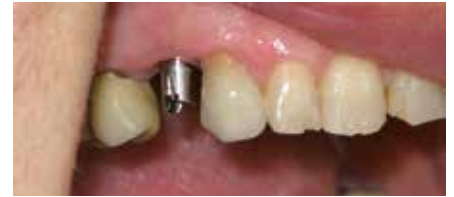

Fig 16.

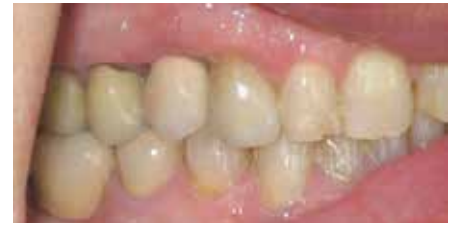

Fig 17.

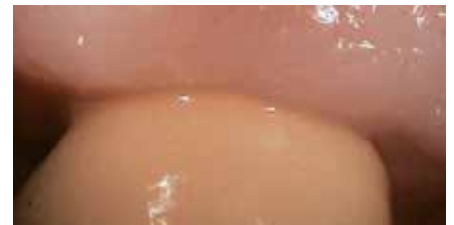

Fig 18.

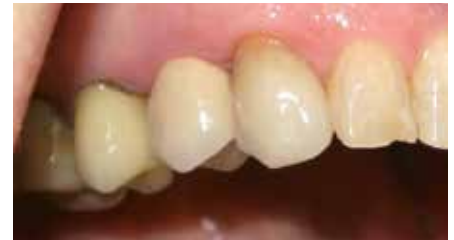

Fig 19.

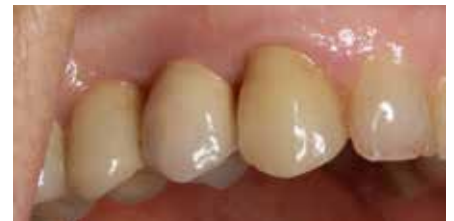

Fig 20.

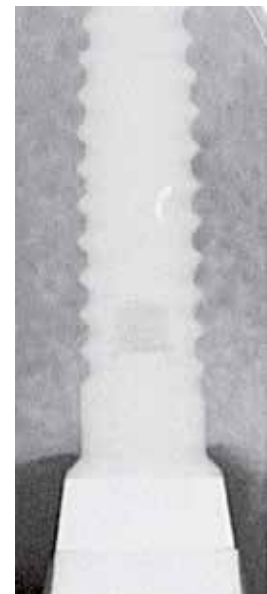

Fig 21.

• Trauma to the bone.

The cover screw was removed (fig 14), and a probe was used along the space between the zirconia collar of the implant and the gingiva to determine the status of the periodontal attachment. Thanks to the biocompatibility of the Z1's zirconia collar, effective epithelial healing had taken place (fig 15)

### Implant restoration

The abutment and the crown were placed (figs 16 and 17), and the crown fitted with temporary cement for retainment. Once again, there were no

complications: the appearance of the gum around the crown showed the desired stippled consistency, displaying a rough texture but without the presence of bleeding or inflammation (fig 18).

Due to the employment of an in-practice technician, all post-operative procedures could be performed conveniently and efficiently on site.

### Final results

The pleasing results of the implant surgery continued to be seen two years after the operation. Natural papillae

had developed around the crown, compared to the flat appearance of the tissue initially (fig 19).

A full 10 years after surgery, there have been no complications and the implant remains strong and healthy (fig 20). The papillae had continued to grow healthily around the zirconia collar and the crown. Most importantly, there has been no bone cratering (fig 21).

The patient, now aged 70, has expressed her satisfaction with the surgical procedures and her crown a decade after her initial treatment.